

# Surgical Endodontic Management of an Unusual Radicular Cyst with Extensive Calcifications: A Case Report

Rajan Alex, George Liza, Mathew Josey, Yacob Jeason Paul

Department of Conservative Dentistry and Endodontics,  
Annoor Dental College and Hospital, Muvattupuzha

Received: 27-03-2023 Revised: 1-04-2023 Accepted: 11-04-2023

**Keywords:** Calcifying cystic odontogenic tumor, Ossifying fibroma, Adenomatoid odontogenic tumor, Radicular cyst, Calcification.

## Case report

A 54-year-old female patient reported with a swelling over the right anterior tooth region (41 to 43 region) for 8 months attached from alveolar ridge. Small in size initially and gradually increased to the present size.

**On inspection:** a gingival swelling of size 1cm \* 1.5cm, pendulated, non-tender & firm on palpation

**Final diagnosis:** Peripheral ossifying fibroma.

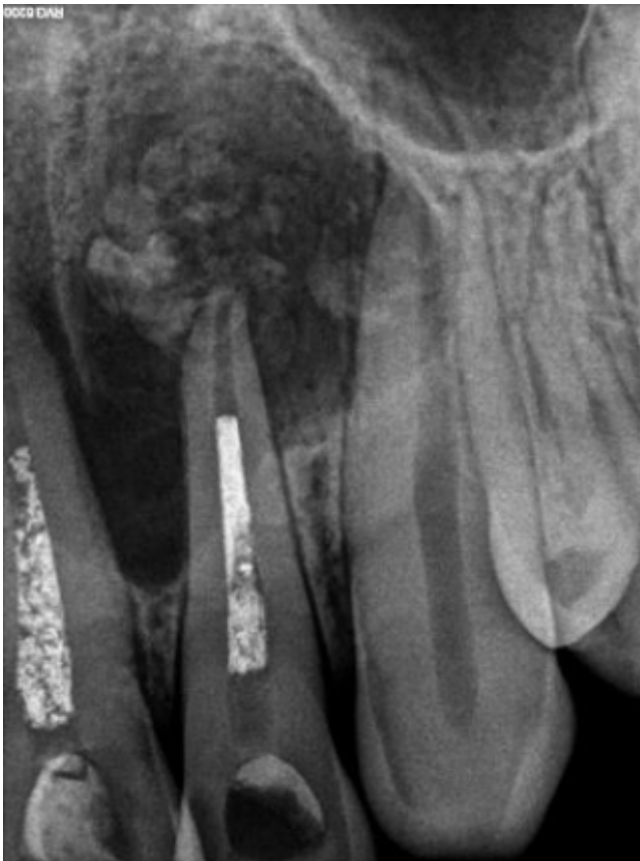
A 22 years old male patient came to the department of Conservative Dentistry and Endodontics with a chief complaint of pain on upper front tooth region since 2 weeks. Patient had a history of trauma from road traffic accident and root canal treatment was initiated 5 years back.

On oral examination – Temporary restoration on 21 and 22 with tenderness on percussion. A sinus tract was present on labial gingival surface between 21 and 22.

### Address for correspondence:

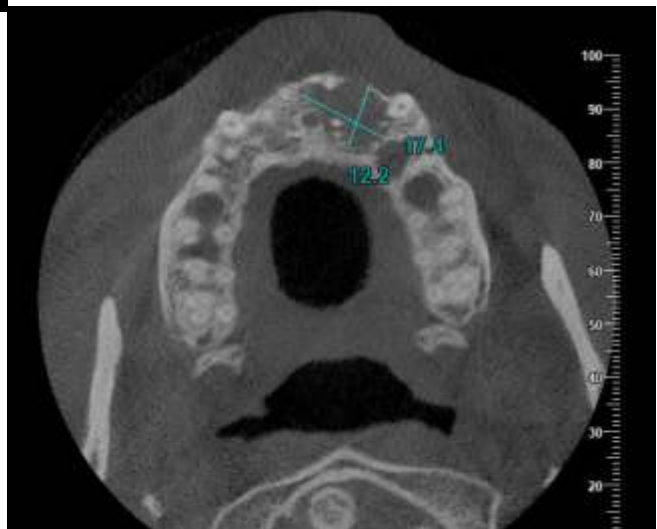
Dr Alex Rajan, Post Graduate,  
Dept of Conservative Dentistry and Endodontics.  
Annoor Dental College & Hospital,  
Muvattupuzha, 686673  
Email ID: alexrajan315@gmail.com

*This is an open access journal, and articles are distributed under the terms of the Creative Commons Attribution-Noncommercial ShareAlike 4.0 license, which allows others to remix, tweak, and build upon the work non-commercially, as long as appropriate credit is given and the new creations are licensed under the identical terms.*



**Fig 1:** IOPA radiograph showing radioopaque material inside root canal of 21, 22 suggestive of previously initiated Root canal treatment. Diffuse periapical well defined radiolucent lesion at the apex of 21,22 with pebbles of calcification.


**Fig 2:** CBCT image showing well defined hypodense lesion extending from the distal aspect of 11 to mesial aspect of 23 (size 11.9 x 19.8mm), with labial bone perforation and involvement of nasopalatine canal.



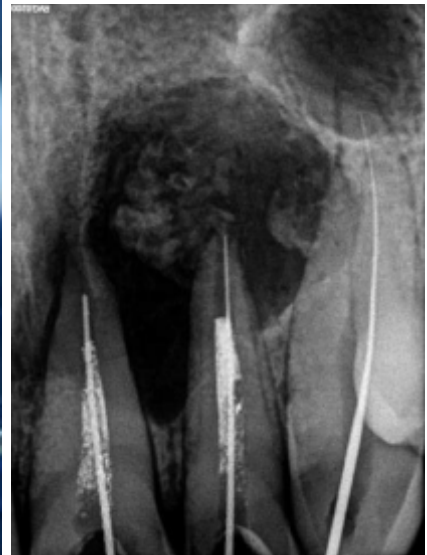
**Differential diagnosis:**

Calcifying cystic odontogenic tumor, Ossifying fibroma and Adenomatoid odontogenic tumor.

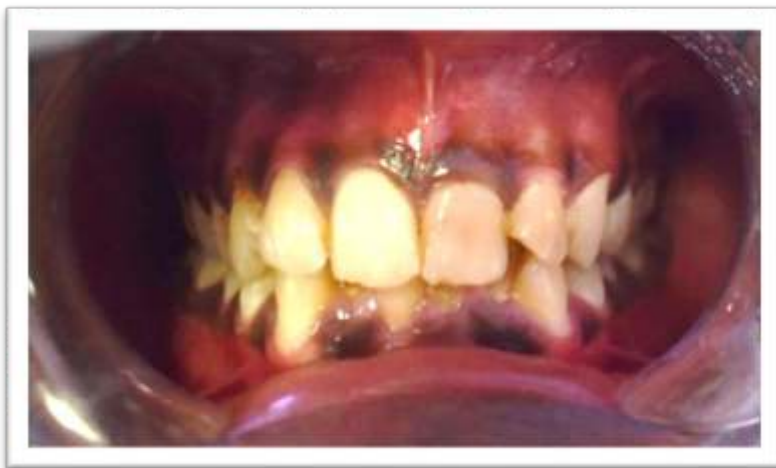**Treatment plan:** Completion of root canal treatment on 21, 22, 23 followed by root resection of 21, 22 and excisional biopsy of the periapical lesion.



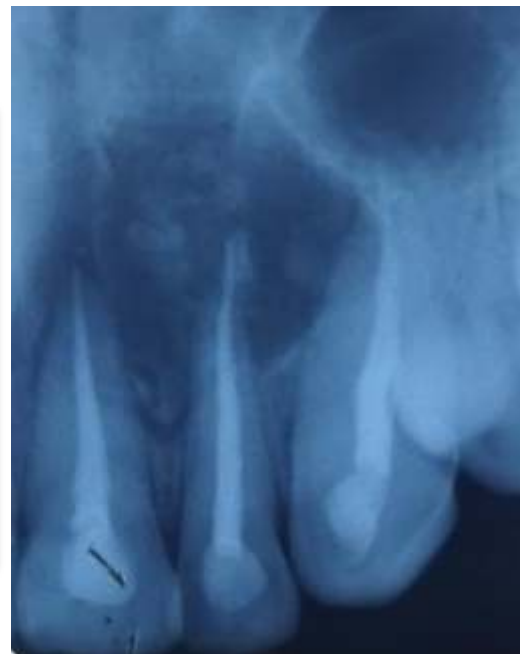**Fig 3:**  
Tooth 21, 22 access opening modified and access opening done on 23.



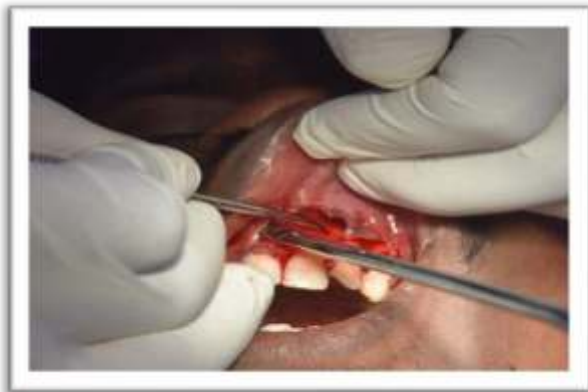**Fig 4:**  
Working length X-Ray of 21, 22, 23



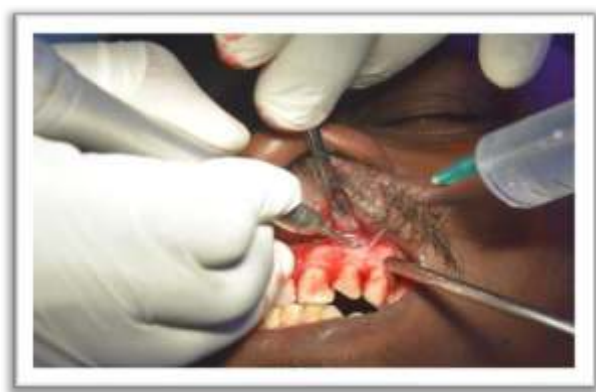**Fig 6:**  
Pre-surgical photograph



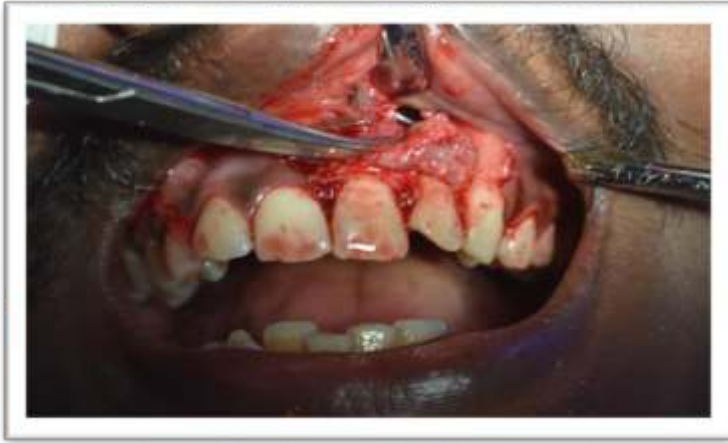**Fig 5:**  
Post Obturation X-Ray 21, 22 and 23



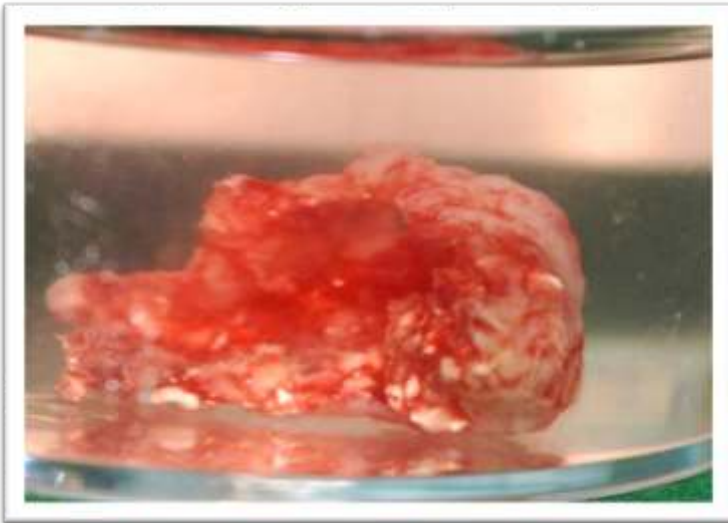
**Fig 7:** Full thickness flap reflected



**Fig 8:** Trephination done

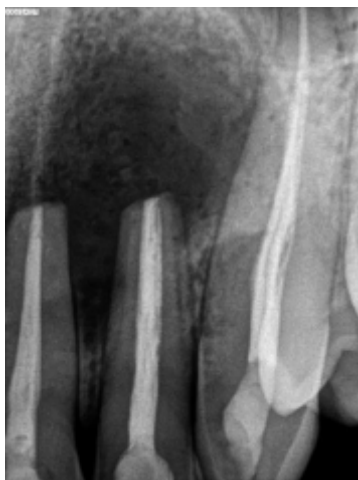

**Fig 9:** Cyst enucleation

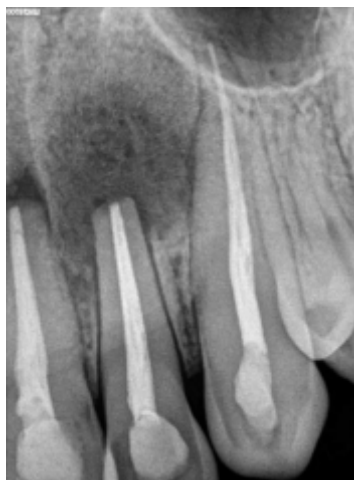

**Fig 10:** Excised specimen showing reddish soft tissue with several yellowish granules with hard consistency.

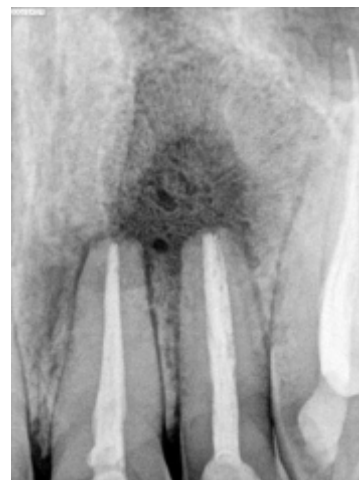
### Histopathology report: Radicular cyst with dystrophic calcification



1 month follow-up radiograph



3 month follow-up radiograph



6 month follow-up radiograph showing healing lesion

**How to cite this article:** Rajan A, George L, Mathew J, Yacob J P. Surgical endodontic management of an Unusual Radicular Cyst with Extensive Calcifications: A Case Report J Oral Biomed Sci 2023; 2:51-4